

Techniques and Procedures



AWAKE LARYNGOSCOPY IN THE EMERGENCY DEPARTMENT

Joseph E. Tonna, MD* and Peter M. C. DeBlieux, MD†

*Division of Cardiothoracic Surgery & Division of Emergency Medicine, Department of Surgery, University of Utah School of Medicine, Salt Lake City, Utah and †Section of Emergency Medicine; Section of Pulmonary and Critical Care, Department of Medicine, Louisiana State University School of Medicine, New Orleans, Louisiana

Reprint Address: Joseph E. Tonna, MD, Division of Cardiothoracic Surgery & Division of Emergency Medicine, Department of Surgery, University of Utah School of Medicine, 30 N. 1900 E., 3C127, Salt Lake City, UT 84132

Abstract—Background: Many emergency physicians gain familiarity with the laryngeal anatomy only during the brief view achieved during rapid sequence induction and intubation. Awake laryngoscopy in the emergency department (ED) is an important and clinically underutilized procedure. **Discussion:** Providing benefit to the emergency physician through a slow, controlled, and deliberate examination of the airway, awake laryngoscopy facilitates confidence in the high-risk airway and eases the evolution to intubation, should it be required. Emergency physicians possess all the tools and skills required to effectively perform this procedure, through either the flexible endoscopic or rigid approaches. The procedure can be conducted utilizing local anesthesia with or without mild sedation, such that patients protect their airway. **Conclusion:** We discuss two clinical scenarios, indications/contraindications, patient selection, and steps to performing two approaches to awake laryngoscopy in the ED. © 2016 Elsevier Inc. All rights reserved.

Keywords—laryngoscopy; awake look; awake intubation; airway management

INTRODUCTION

Awake laryngoscopy in the emergency department (ED) is an important and clinically underutilized procedure of which emergency physicians are capable. Many

emergency physicians gain familiarity with the laryngeal anatomy only during the brief view achieved during rapid sequence induction and intubation. There is benefit to full visualization of the posterior pharynx, larynx, supraglottis, and subglottic structures without compromising hemodynamics or level of consciousness in the patient in whom there is concern for acute and evolving pathology, including potential loss of airway patency. Direct knowledge of the anatomy and condition of the aforementioned structures enables the clinician to make an informed decision about the necessary management of the presenting problem, and specifically, the best approach to securing the airway. Airway assessment in the ED focuses on the rapid determination of airway anatomy and oxygenation (Figure 1), which guides the appropriate course of intervention (1). As such, it is in the patient with normal or especially abnormal anatomy, yet normal oxygenation, that awake laryngoscopy is appropriate, separate from, or as a prelude to, intubation.

DISCUSSION

Case 1

A 65-year-old woman with a recent history of laryngeal cancer presented to the ED for fever. Her past medical history included the laryngeal cancer, for which she was scheduled to undergo surgery the following week. Her vitals were: heart rate 110 beats/min, respiratory

	Is anatomy normal or abnormal?	
Is oxygenation adequate?	Normal Anatomy Adequate Oxygenation	Abnormal Anatomy Adequate Oxygenation
	Normal Anatomy Inadequate Oxygenation	Abnormal Anatomy Inadequate Oxygenation

Figure 1. Emergency Airway Assessment. From Vissers RJ, Gibbs MA. The high-risk airway. *Emergency Med Clin North Am* 2010;28:203–17.

rate 25 breaths/min, temperature 39°C, O₂ Sat 95%, and blood pressure 95/70 mm Hg. Over the first hour, it became clear that she was worsening from severe sepsis and may need to be intubated. She said, “I’m a difficult intubation, doc.” The practitioner might wonder what her laryngeal anatomy looked like.

Case 2

A 55-year-old woman presented to the ED by emergency medical services (EMS) for facial swelling. EMS reported that she had a history of angioedema from medications. On examination, her oropharyngeal orifice was nearly occluded by her tongue. She was very anxious and having some increased work of breathing. The practitioner was concerned about how far posteriorly her oropharyngeal swelling went.

Approach

In preparing for awake laryngoscopy, the emergency physician should make an assessment of the available approaches and resources at their disposal, including rigid (oral) and flexible endoscopic (oral or nasal) approaches. Although traditional direct *rigid* laryngoscopy is comfortable for many emergency physicians and often can provide adequate glottic views, for the purposes of awake laryngoscopy without muscle relaxants or deep sedation, alignment of the oral, pharyngeal, and laryngeal axes is very difficult. For the purposes of awake laryngoscopy in the ED, we recommend rigid (video)endoscopic laryngoscopes or flexible (video)endoscopes.

In choosing among these, the first question that needs to be asked is whether the anatomy is likely to be consistent with a rigid laryngoscopic view (Figure 2). Primarily, this depends on whether an adequate view can be achieved by simply viewing around the corner of the oropharyngeal/laryngeal axis interface in one plane, or whether complex anatomy requires movement in two or more anatomic planes. The former group may be viewed through a rigid approach; patients in this group may include those with cervical immobilization, fusion,

arthritis or spondylitis, micrognathia, and an anterior larynx, as all of these conditions pose barriers to traditional direct alignment of the oropharyngeal and laryngeal axes, but are facilitated by using hyperangulated rigid endoscopic laryngoscopy, for which there are many tools (e.g., Glidescope [Verathon, Seattle, WA], McGrath [Aircraft Medical, Edinburgh, UK], C-MAC D blade [Karl Storz, Tuttlingen, Germany]). Conversely, the latter group includes patients with acutely distorted anatomy such as oropharyngeal and labial edema or tracheal deviation, small mouth opening, sublingual or deep space infections, and those with known abnormal laryngeal anatomy, including previous radiation or neck surgery. These are situations in which anatomic barriers may prohibit placing a rigid laryngoscope or in which the view obtained by movement through only one plane is inadequate; these situations may require flexible endoscopic laryngoscopy to navigate in two planes (Table 1).

Preparation and Patient Selection

Awake laryngoscopy is predicated on the patient maintaining his or her own airway reflexes and ventilatory drive. Airway reflexes are blunted by local anesthetics. Thus, although awake laryngoscopy can be completed utilizing topical anesthesia without systemic sedation, there are situations in which airway patency may still be lost. Airway patency is both reflexive and volitional, and in patients with depressed levels of consciousness who lack volitional control of their airway, administration of topical anesthesia—and blunting of reflexive control—may result in loss of airway.

Secondly, if awake laryngoscopy is indicated and planned, the clinician must feel comfortable that there is adequate time to prepare and carry out the procedure. Even in the presence of experienced providers, awake laryngoscopy will typically require at least 10 to 15 min. Dynamic evolution of hemodynamics, ventilatory drive, oxygenation, and airway patency needs to be anticipated, and a contingency plan must be reviewed and discussed with the care team prior to moving forward, or patient safety will be compromised. Patients with baseline hypoxia, uncompensated hypercapnia, hemodynamic instability, agitation, and developmental barriers to participation are poor candidates for awake laryngoscopy.

The requirement for supplemental oxygen is not necessarily a contraindication to awake laryngoscopy. Oxygen can be administered throughout the application of anesthesia and during the flexible laryngoscopy using a modified nonrebreather mask (Figure 3). Additionally, working port adapters can be attached to noninvasive positive pressure ventilation masks (bilevel positive airway pressure/continuous positive airway pressure) enabling

Approach to Awake Laryngoscopy

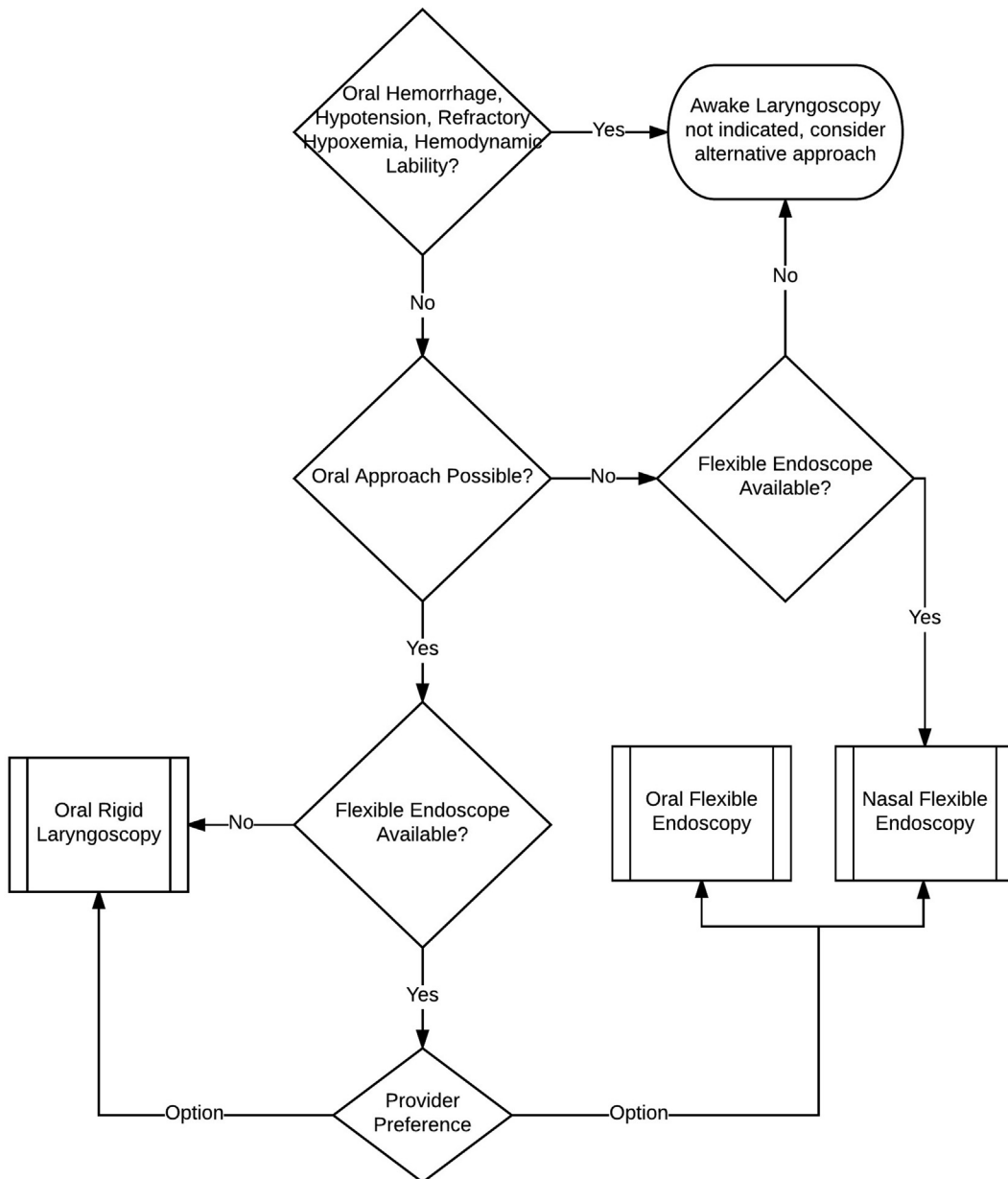


Figure 2. Awake laryngoscopy flow diagram.

flexible endoscopic laryngoscopy during positive pressure oxygenation (Figure 4).

Topical Anesthesia

Desiccation. Desiccation of the oral, nasal, pharyngeal, and laryngeal mucosa facilitates anesthetic absorption and limits secretions (2). In the ED, desiccation can be achieved through the prompt administration of 0.4 mg of glycopyrrolate intravenously upon consideration of

awake laryngoscopy, or at least 30 min prior to the application of topical medications (Table 2).

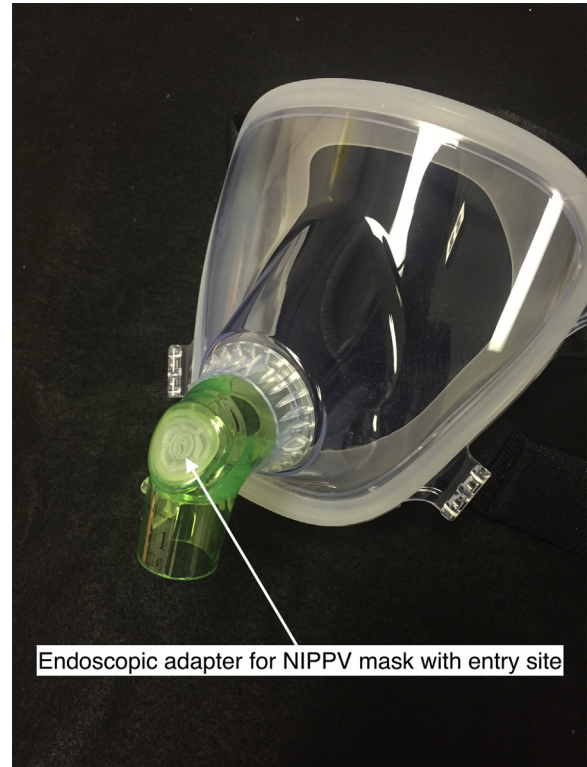Topical anesthesia. Effective topical anesthesia is of paramount importance with awake laryngoscopy—with or without a sedative (Figure 5). Attempts without topical anesthesia will be uncomfortable for the patient, and are unlikely to be successful. Because direct manipulation of the posterior pharyngeal and laryngeal structures is highly stimulating, dense topical anesthesia enables

Table 1. Potential Barriers to Rigid Laryngoscopy and Contraindications to Awake Laryngoscopy (Relative)

Potential barriers to rigid laryngoscopy
Angioedema
Lingual edema
Sublingual abscess
Small oropharyngeal orifice
Tracheal edema
Known laryngeal abnormality (including previous radiation or laryngeal surgery)
Contraindications to awake laryngoscopy (relative)
Uncorrectable hypoxemia
Hypercarbia
Inability to protect airway
Active oral hemorrhage, hemoptysis or hematemesis
Active vomiting
Hemodynamic instability

painless awake laryngoscopy without any sedation in many patients (3–6). Conversely, without topical anesthesia, laryngoscopy is likely to stimulate patients to unsafe levels during the procedure.

For the mucosal surfaces of the mouth, pharynx, and larynx, short-acting topical anesthetics (e.g., lidocaine, tetracaine) should be used. Long-acting topical anesthetics such as bupivacaine should be avoided. For the inexperienced laryngoscopist, we recommend a lower-dilution anesthetic such as 1% lidocaine, rather than

**Figure 3. Modified oxygen mask.****Figure 4. Modified noninvasive positive pressure ventilation (NIPPV) mask with flexible endoscope adapter.**

4%, due to adequate efficacy with lower dilutions and the greater volume that can be administered prior to toxicity (Supplementary Figure 1A–D and 2A–F, available online) (7–9).

Oral Anesthesia

Many texts advocate utilizing nebulized lidocaine for nasopharyngeal, oropharyngeal, and laryngeal anesthesia, but the efficacy of anesthesia in these areas is variable and so we do not routinely recommend nebulization (5,10–12).

Gargling. The best initial application of anesthetic is having the patient gargle 40 mg of liquid lidocaine (4 cc of 1%). This solution should be discarded after 1–2 min of gargling. This maneuver can provide a dense supraglottic, vocal fold, and arytenoid anesthesia.

Ointment to tongue. Secondly, additional anesthesia should be provided by application of 5 cc of 4% lidocaine ointment (200 mg) to the posterior tongue. This is administered via a tongue depressor to the posterior tongue, then asking the patient to let the ointment melt in his/her mouth for a few minutes prior to swallowing. Ointment is superior to jelly because as it heats up, it will

Table 2. Medications and Sedatives

Anesthesia	Vasoconstriction	Anesthesia + Vasoconstriction	Desiccation
Medications Lidocaine 1% solution Lidocaine 4% solution Lidocaine 4% ointment Lidocaine 4% jelly	Oxymetazoline 0.05% solution Phenylephrine 0.25% solution	Cocaine 4% solution	Glycopyrrolate mg i.v. once Atropine 0.5 mg i.v. once
		Dose	Side Effects
Sedative			
Dexmedetomidine (Precedex®)		0.3–1.2 µg/kg/h	Hypotension, bradycardia
Ketamine		1–2 mg/kg i.v. bolus 4–5 mg/kg i.m. bolus	Hypersalivation, bronchorrhoea
Midazolam [Versed®]		1–2 mg i.v. bolus p.r.n.	Apnea, hypotension

i.v. = intravenously; i.m. = intramuscularly; p.r.n. = pro re nata (as needed).

melt, decrease in viscosity, and drain posteriorly to the esophagus, coating the mucosal surfaces of the posterior and inferior pharynx and supraglottis.

Atomization. The last application of anesthetic should be 5–10 cc of 1% (50–100 mg) lidocaine liquid through an atomizer device. LMA makes an ideally designed disposable atomizer wand and syringe for this purpose (LMA

MADgic®; Teleflex Medical Europe Ltd., Westmeath, Ireland). This malleable device administers a fine mist directed at the area of interest in a controlled fashion. For the oral approach, the atomizer should be gently curved and advanced sequentially into the oropharynx, starting with the uvula and soft palate and advancing toward the posterior pharyngeal wall and deeper toward the larynx. Spraying should be performed sequentially with each new placement, until the wand actually contacts the pyriform sinuses and supraglottis ([Supplementary Figure 1D](#)). The laryngoscopist can be assured that the spray is being applied appropriately to the supraglottis and vocal folds when the patient coughs and sputters with each spray. Within a few applications the supraglottis will be anesthetized and the patient's cough reflex will abate ([Figure 6](#)).

Prepared Hurricaine® (benzocaine 20%; Beutlich Pharmaceuticals, Bunnell, FL) or Cetacaine® (benzocaine 14%, tetracaine 4%; Cetylite Inc., Pennsauken, NJ) spray may be more familiar to many clinicians, but this method of anesthesia carries the risk of benzocaine overdose and methemoglobinemia and is not advised ([Table 3](#)).

Toxicity. Application of the listed doses will result in a total dose of 290–420 mg of lidocaine. In studies, oropharyngeal application results in lower blood levels when compared with inhalation or injection, but because topical, oral, and nebulized lidocaine are variably absorbed, clinicians should assume total administered dose is absorbed and active, and administer < 5 mg/kg ([13,14](#)). This is well established as a safe threshold for multimodal anesthetic administration, and this is also the dose above which toxic plasma levels (5 µg/mL) from topical and inhalational administration have been demonstrated ([15,16](#)).

Nasal anesthesia. The anesthesia described in the Oral Approach is necessary, but additional anesthesia and vasoconstriction must be provided to the nasal mucosa

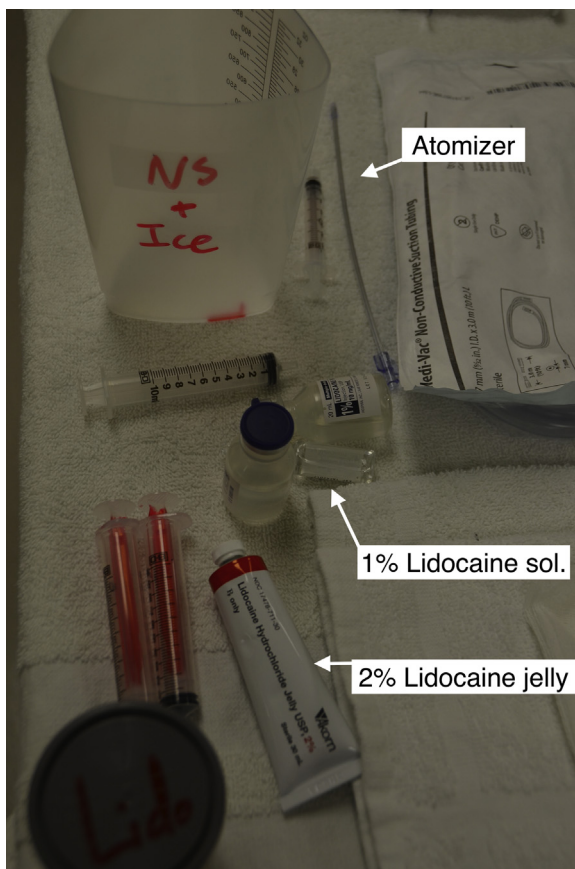


Figure 5. Preparation (lidocaine jelly, 1% solution, atomizer).

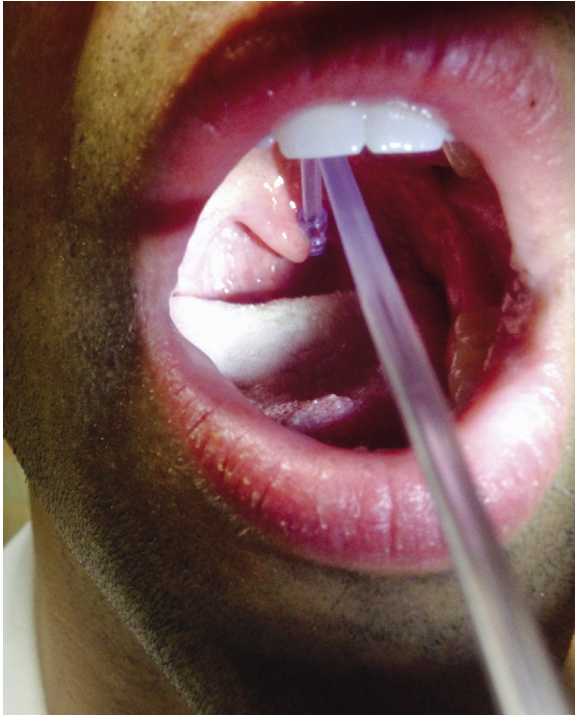

Figure 6. Using LMA MADgic® with lidocaine to anesthetize the posterior oropharynx.

if this approach is considered to minimize bleeding and edema. This can be achieved using a local anesthetic with vasoconstrictive properties (e.g., cocaine) alone or by mixing topical vasoconstrictors (phenylephrine, oxymetazoline [Afrin®; Bayer, Whippany, NJ]) with the lidocaine (Figure 7) (17,18). Notice in the image that there is a small rise of the nasal floor upon entering, necessitating angling inferiorly after passing deep to it, to pass below the inferior turbinate and not above. A common mistake is to pass between the inferior and middle turbinates.

The patient can often report which naris is more patent, and preparation of that naris can ensue. The application of 4% cocaine with cotton-tipped applicators is a directed and efficacious method. These should be soaked, inserted gently parallel to the floor of the turbinate and inferior to the inferior turbinate, and advanced about 1 cm at a time (after 30–60 s). As the cocaine contacts the nasal mucosa, the patient will feel pressure and sometimes a mild burning that will give way to eventual

Table 3. Steps of Oral Topical Anesthesia

Steps of Oral Topical Anesthesia
4 cc of 1% lidocaine gargled, spit out (40 mg)
5 cc of 4% or 5% lidocaine ointment (preferable to jelly) to posterior tongue (200–250 mg)
5–10 cc of 1% lidocaine through atomizer to posterior pharynx, supraglottis (50–100 mg)

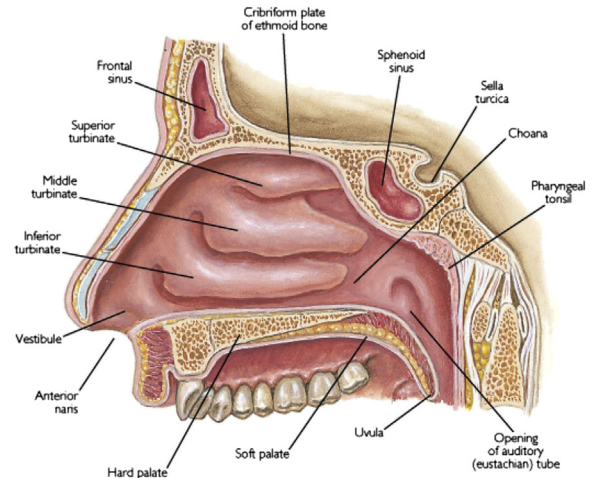


Figure 7. Nasal turbinates (17).

anesthesia and improved patency. The applicator can be advanced, intermittently removing and re-soaking in cocaine, until it has touched the posterior wall of the nasal cavity, often > 10 cm deep. As the tract opens, a second soaked applicator can be advanced just behind or adjacent to the first, creating a wider tract. Two applicators are generally sufficient.

If 4% cocaine is not available, a mixture of lidocaine gel (2–4%) + 0.25% phenylephrine or lidocaine gel + 0.05% oxymetazoline (Afrin) works equally well (18–20).

A useful alternative to using cotton-tipped applicators is to use an atomizer or MADgic device and sequentially spray the mixture along the tract, followed by insertion of a lidocaine jelly-coated nasal trumpet along the pathway for dilatation (Supplementary Figures 1 and 2).

Sedation

After appropriate topical analgesia, many patients require little or no sedation. If a patient seems to require significant sedation, the clinician should be clear if it is due to peri-procedural anxiety or inadequate anesthesia. Sedation for the latter is inappropriate and can be potentially dangerous once the procedure has begun.

Laryngoscopy is a stimulating, though not necessarily painful, procedure due to the density of nerves in the area being instrumented, specifically the posterior oropharynx, the peri-arytenoid area and especially within the vallecula. For this reason, topical anesthesia has fewer side effects than sedation and addresses the specific cause of stimulation during laryngoscopy. Empirically starting with sedation to try to treat a need for topical anesthesia or analgesia will result in more sedation than is necessary, especially once the stimulus is removed (Table 2).

There will be times when topical anesthetics are unavailable or lack sufficient efficacy. In these cases the

use of intravenous sedatives may be indicated. In these circumstances the use of sedatives with minimal respiratory blunting, rapid onset, short half-life, and limited hemodynamic impact offer the best patient safety profile. Prior to the administration of sedatives, the treatment team should have specific and detailed treatment plan discussions to establish a shared mental model regarding goals of care and alternative approaches. The team should be prepared to rapidly shift from awake laryngoscopic treatment goals in the settings of hemodynamic compromise, apnea, or oxygen desaturations not responding to supplemental oxygen (Table 1).

Ketamine. Ketamine is a familiar drug to most emergency physicians and ideal for ED laryngoscopy. Ketamine can be given as a slow bolus (0.3–0.5 mg/kg intravenously over 5 min). Ketamine will not cause suppression of the respiratory drive and the patient will maintain normal airway reflexes. Ketamine causes bronchorrhea and salivation, making the early administration of glycopyrrolate important. This agent can bolster hemodynamics and typically raises heart rate and blood pressure.

Midazolam (Versed®; Roche, Basel, Switzerland). Midazolam, in a small bolus to patients who have already received adequate topical anesthesia, can blunt any anxiety to laryngoscopy without significantly depressing respiratory drive. We recommend it be given in 1-mg boluses, up to 2 mg, at the beginning of the procedure. Midazolam also provides antiemetic properties, which can be helpful during manipulation of the gag receptors.

Technique

Awake laryngoscopy is most easily achieved with rigid endoscopic and flexible endoscopic instruments.

Rigid Endoscopic Laryngoscopy

Rigid endoscopes are commonly hyperangulated, and enable “around the corner” visualization without alignment of the oral, pharyngeal, and laryngeal axes. As such, rigid endoscopic laryngoscopy can easily be done with topical anesthesia, or brief systemic sedation, without the neuromuscular blockade.

Awake rigid laryngoscopy can be achieved through a traditional laryngoscopist’s view in which the patient lies supine and the laryngoscopist stands at the head of the bed. Alternatively, one can use the “Tomahawk” approach, which enables the patient to remain sitting, with the provider “face to face” and the video screen turned to the provider (21).

Steps

With either approach, the laryngoscope, after lubrication is applied to the concave surface, is placed on the tongue, and advanced posteriorly along the lingual surface towards the vallecula. If able, patients should hyperextend their neck to better align the laryngeal structures (22). Due to the forward position of the camera on many video-laryngoscopes, an adequate glottic view is often achieved early in this process. For the purposes of ED awake laryngoscopy, we recommend a hyperacute angle blade (traditional Glidescope or C-MAC D Blade), as this has been shown to facilitate a more adequate glottic view (22).

Flexible Endoscopic Laryngoscopy

A flexible endoscope (traditionally called fiberoptic) has the benefits of being able to be passed through the nose in patients with lingual or labial swelling and can be used to move through two planes of motion in patients with distorted anatomy (Table 1). Flexible endoscopes may provide a better view of the glottis, though this approach takes slightly longer (21,23). Compared with an oral approach, nasal-approach flexible endoscopy naturally aligns the endoscopic view with the full glottis, and the endoscope is less mobile throughout patient movement. Despite this, it is our experience that the need for posterior pharyngeal anesthesia is similar with both rigid and flexible approaches, as it is difficult to avoid touching pharyngeal structures with the flexible endoscope. We suggest that in patients without a clear indication for flexible laryngoscopy (Table 1), clinicians use the instrument with which they are most comfortable, which will most often be a rigid endoscopic approach.

Steps—Oral Approach

When using an oral-approach flexible endoscope, it is of paramount importance that a circular endoscopic bite block is placed, as patients will reflexively bite down on endoscopes if inadequately anesthetized, often destroying the scope. The endoscope is passed through the bite block into the mouth, and advanced to just before the posterior pharyngeal wall, as with the atomizer. The scope is down-flexed and advanced behind the tongue.

Steps—Nasal Approach

If a nasal approach is used, the scope is placed into the nares and advanced gently, parallel to the nasal floor. Once the endoscope has begun to pass the nares, the provider should advance using the live endoscopic view. Nearing the posterior pharyngeal wall, the scope is again down-flexed and advanced.

Case 1 Conclusion

After using lidocaine jelly on the tongue with topical atomization to the posterior pharynx, you easily insert a rigid hyperangulated endoscope in a “tomahawk” fashion without requiring sedation. The patient’s laryngeal structures easily come into view and are inflamed (Supplementary Figure 2F), but her airway is patent. You understand the risks of repeated airway instrumentation, but given her laryngeal cancer and her current stability, you start steroids, call her otolaryngologist, and admit her to the intensive care unit for monitoring and sepsis care.

Case 2 Conclusion

Given the lingual swelling, you opt to enter through the nose with a flexible endoscope. After applying lidocaine through an atomizer to the nose and posterior pharynx, and lidocaine jelly and oxymetazoline to the nose, you pass a flexible endoscope along the floor of the nose (Supplementary Figure 2B), past the base of the tongue (Supplementary Figure 2D) and to the level of the larynx. You find that despite her tongue swelling, she has no swelling at the level of her larynx (Supplementary Figure 2E) and are reassured.

CONCLUSION

Awake laryngoscopy enables the emergency physician a controlled and prolonged examination of the airway. Patients with predicted normal and abnormal airway anatomy, yet normal oxygenation and mental status, are ideal candidates. Preparation begins at the moment it is considered, starting with administration of glycopyrrolate for desiccation, followed by preoxygenation and topical agents for anesthesia with or without vasoconstriction. The choice of rigid oral laryngoscopy or flexible endoscopic approaches is primarily decided by physician comfort with each instrument and the patient’s oral anatomy. Awake laryngoscopy reveals the otherwise hidden features of the oropharyngeal and laryngeal spaces, bestowing understanding and confidence. In an individual patient, airway reflexes are maintained, allowing the emergency physician the luxury of a full upper airway examination in preparation for the potential of an intubation.

SUPPLEMENTARY DATA

Supplementary data related to this article can be found at <http://dx.doi.org/10.1016/j.jemermed.2016.11.013>.

REFERENCES

1. Vissers RJ, Gibbs MA. The high-risk airway. *Emerg Med Clin North Am* 2010;28:203–17.

2. Brookman CA, Teh HP, Morrison LM. Anticholinergics improve fiberoptic intubating conditions during general anaesthesia. *Can J Anaesth* 1997;44:165–7.
3. Stoelting RK. Circulatory response to laryngoscopy and tracheal intubation with or without prior oropharyngeal viscous lidocaine. *Anesth Analg* 1977;56:618–21.
4. Kovac AL. Controlling the hemodynamic response to laryngoscopy and endotracheal intubation. *J Clin Anesth* 1996;8:63–79.
5. Venus B, Polassani V, Pham CG. Effects of aerosolized lidocaine on circulatory responses to laryngoscopy and tracheal intubation. *Crit Care Med* 1984;12:391–4.
6. Williams KA, Barker GL, Harwood RJ, Woodall NM. Combined nebulization and spray-as-you-go topical local anaesthesia of the airway. *Br J Anaesth* 2005;95:549–53.
7. Wikipedia. Aryepiglottic fold. Gray’s anatomy (1918). Available at: <https://upload.wikimedia.org/wikipedia/commons/6/62/Gray955.png>. Accessed February 16, 2016.
8. Wiczorek PM, Schrickler T, Vinet B, Backman SB. Airway topicalisation in morbidly obese patients using atomised lidocaine: 2% compared with 4%. *Anaesthesia* 2007;62:984–8.
9. Xue FS, Liu HP, He N, et al. Spray-as-you-go airway topical anesthesia in patients with a difficult airway: a randomized, double-blind comparison of 2% and 4% lidocaine. *Anesth Analg* 2009;108:536–43.
10. In: Miller’s anaesthesia: Miller RD, Eriksson LI, Fleisher LA, Wiener-Kronish JP, Cohen NH, Young WL, eds. Airway management in the adult. Philadelphia: Elsevier Health Sciences; 2014.
11. Laurito CE, Baughman VL, Becker GL, Polek WV, Riegler FX, VadeBoncouer TR. Effects of aerosolized and/or intravenous lidocaine on hemodynamic responses to laryngoscopy and intubation in outpatients. *Anesth Analg* 1988;67:389.
12. Baronia AK, Singh PK, Maheshwari A, Jain VK, Mittal P, Pant KC. Inhaled lidocaine for prevention of hemodynamic changes in laryngoscopy and intubation. *J Neurosurg Anesthesiol* 1992;4:154–9.
13. Greenblatt DJ, Benjamin DM, Willis CR, Harmatz JS, Zinny MA. Lidocaine plasma concentrations following administration of intraoral lidocaine solution. *Arch Otolaryngol* 1985;111:298–300.
14. Nydahl PA, Axelsson K. Venous blood concentration of lidocaine after nasopharyngeal application of 2% lidocaine gel. *Acta Anaesthesiol Scand* 1988;32:135–9.
15. Frey WC, Emmons EE, Morris MJ. Safety of high dose lidocaine in flexible bronchoscopy. *J Bronchol Intervent Pulmonol* 2008;15:33–7.
16. Labedzki L, Ochs HR, Abernethy DR, Greenblatt DJ. Potentially toxic serum lidocaine concentrations following spray anesthesia for bronchoscopy. *Klin Wochenschr* 1983;61:379–80.
17. The External Nose. ENT for medical students: Nose – Anatomy & Physiology. Available at: https://www.google.com/url?sa=i&rct=j&q=&esrc=s&source=images&cd=&cad=rja&uact=8&ved=0ahUKEwjQobyV5o_PAhUL3WMKHcOpCLcQjhwIBQ&url=ht tp%3A%2F%2Fent4students.blogspot.com%2F2012%2F12%2Fnose-anatomy.html&psig=AFQjCNFSLdaK-zigrM03QENpjd14vS3fIA&ust=1473974802162981. Accessed February 12, 2016.
18. Gross JB, Hartigan ML, Schaffer DW. A suitable substitute for 4% cocaine before blind nasotracheal intubation: 3% lidocaine-0.25% phenylephrine nasal spray. *Anesth Analg* 1984;63:915–8.
19. Tarver CP, Noorily AD, Sakai CS. A comparison of cocaine vs. lidocaine with oxymetazoline for use in nasal procedures. *Otolaryngol Head Neck Surg* 1993;109:653–9.
20. Meyer DR. Comparison of oxymetazoline and lidocaine versus cocaine for outpatient dacryocystorhinostomy. *Ophthal Plast Reconstr Surg* 2000;16:201–5.
21. Silverton NA, Youngquist ST, Mallin MP, et al. GlideScope versus flexible fiber optic for awake upright laryngoscopy. *Ann Emerg Med* 2012;59:159–64.
22. Dreguis AS, Carlson JN. GlideScope vs. C-MAC for awake upright laryngoscopy. *J Emerg Med* 2015;49:361–8.
23. Yumul R, Elvir-Lazo OL, White PF, et al. Comparison of the C-MAC video laryngoscope to a flexible fiberoptic scope for intubation with cervical spine immobilization. *J Clin Anesth* 2016;31:46–52.